Myocardial Ischemia,
A Rare Presentation of Meckel's Diverticulum

Trevor Nessel MS-III[ab]; Connor Kerndt, MS-4[a]; Zaid Shareef, MS-III[a]; Christopher Doig, D.O.

a Michigan State University College of Osteopathic Medicine, East Lansing, Michigan, USA b Department of Internal Medicine, Garden City Hospital, Garden City, Michigan, USA

Introduction

Meckel's diverticulum (MD) represents the most common congenital defect of the gastrointestinal (GI) system. MD is a true diverticulum that remains as a remnant of the omphalomesenteric duct, which connects to the yolk-sac during embryogenesis. The failed involution leaves the remnant MD which generally fails to induce symptoms or complications in a majority of those affected. Studies predict their prevalence to be about 1.2% of the general population of which only 2% will present with complication in their lifetime. A majority of patients report no symptoms and MD is found incidentally while working up another medical problem. However, it is important to note that Meckel's diverticulum can result in dangerous complications in the adult population including bowel obstruction, intussusception, diverticulitis, perforation, and hemorrhage at a rates higher than one would expect. Of symptomatic adults with MD, bowel obstruction is the most common presentation, followed by inflammation and bleeding (Figure 1a). While GI bleeding in the elderly is more commonly related to pathology such as diverticulosis, colitis, and hemorrhoids (Figure 1b), and these diagnoses generally render many potential culprits to their etiology, MD should not be overlooked as a possible cause. This case represents an atypical presentation of MD manifesting as an NSTEMI.

Hospital Course

An 82-year-old man with a history of recent myocardial infarction presented with a two-day history of emesis and hematochezia with subsequent syncope. Other past medical history includes coronary artery disease, dyslipidemia, GERD, and bleeding duodenal ulcer. Vitals revealed a BP 116/59mmgHg and HR 92bpm. Laboratory testing showed a hemoglobin of 6.7g/dl with leukocytosis and lactic acidosis (Table 1). Physical exam uncovered blood within the rectum. While in the emergency department, the patient started complaining of substernal chest pain. Electrocardiogram demonstrated ST-segment depression in the anterior leads with concurrent troponin elevation, suggestive of myocardial ischemia (Figure 2; Table 1). After treatment with nitroglycerin and an initial blood transfusion, the patient was transferred to the ICU for further monitoring.

CT of the abdomen initially revealed no signs of acute gastrointestinal bleed and was followed by emergent esophagogastroduodenoscopy, also without identification of the bleeding source (Figure 3a). A repeat CT scan with contrast was performed the following day revealing active diverticular bleeding near the hepatic flexure and was confirmed with focal uptake on tagged-RBC Technetium 99 scan (Figure 3b&c, respectively). Arterial embolization was performed but unsuccessful in stopping the bleed (Figure 3d).

By day 3, the WBC was still elevated, while the hemoglobin, hematocrit, RBC, and platelets were still below normal (Table 2). The patient's resulting hemodynamic stability deteriorated despite numerous blood transfusions and thus he underwent an emergent exploratory laparotomy for treatment of the GI bleed. Surgery revealed a bleeding, infarcted MD with corresponding infarcted portion of ileum which were both were resected, stopping the bleed (Figure 4). After the procedure, the patient's hemoglobin increased to 12.2 g/dL as the hematochezia gradually tapered to a halt by postoperative day 6. Over the course of the hospital stay, the patient underwent 22 transfused units of packed red blood cells, along with 11 units of fresh frozen plasma, and 4 units of platelets. The patient was sent to in-patient rehabilitation on hospital day 10.

References

1. Hansen CC, Søreide K. Systematic review of epidemiology, presentation, and management of Meckel's diverticulum in the 21st century. Med (United States). 2018;97(35). doi:10.1097/MD.0000000000012154
2. Strate LL. Lower GI bleeding: Epidemiology and diagnosis. Gastroenterol Clin North Am. 2005;34(4):643-664. doi:10.1016/j.gtc.2005.08.007
3. Sagar, J., Kumar, V., & Shah, D. K. (2006). Meckel's diverticulum: a systematic review. Journal of the Royal Society of Medicine, 99(10), 501–505. https://doi.org/10.1258/jrsm.99.10.501
4. Simms, M. H., & Corkery, J. J. (1980). Meckel's diverticulum: its association with congenital malformation and the significance of atypical morphology. The British Journal of Surgery, 67(3), 216–219. https://doi.org/10.1002/bjs.1800670316
5. Soltero, M. J., & Bill, A. H. (1976). The natural history of Meckel's diverticulum and its relation to incidental removal. A study of 202 cases of diseased Meckel's diverticulum found in King County, Washington, over a fifteen year period. The American Journal of Surgery, 132(2), 168–173. https://doi.org/10.1016/0002-9610(76)90043-X
6. Uebernickel, T., Meyer, L., Koch, A., Hinkel, M., Kube, R., & Gastinger, I. (2005). The significance of Meckel's diverticulum in appendicitis--a retrospective analysis of 233 cases. World Journal of Surgery, 29(4), 455–458. https://doi.org/10.1007/s00268-004-7615-x
7. Yakoubovitz, E. K., Marano, A. F., Eisenstat, J. C. F., & Fingerhut, A. L. (2001). Meckel's diverticulum. Journal of the American College of Surgeons, 192(5), 658–662. https://doi.org/10.1016/S1072-7515(01)00817-1
8. Pollack, E. S. (1996). Pediatric abdominal surgical emergencies. Pediatric Annals, 25(8), 448–457. https://doi.org/10.3928/0090-4481-19960801-08

Background Information



Figure 1: Demonstrates statistics involving gastrointestinal bleeds in adults. (a) Illustrates the most common presenting symptoms in symptomatic adult MD patients, from a study including a population of 289 patients. (b) Shows the most common sources of adult GI bleeds taken from 5 studies, consisting of 1587 patients from 1975-2000.

Clinical Testing

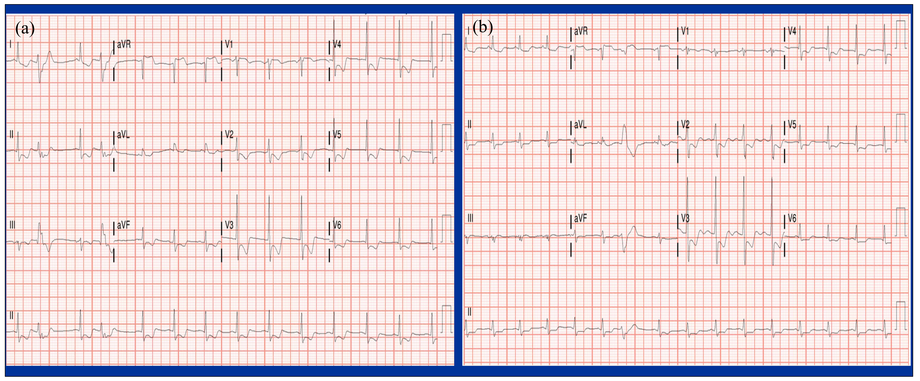

Figure 2: EKGs on (a) Day 1 of hospital admission vs (b) Day 3 of hospital admission, both taken after acute onset chest pain. Findings: (a) Sinus rhythm; Abnormal R-wave progression, early transition; Repolarization abnormality plus ST depressions in anterolateral leads, suggestive of ischemia. (b) Sinus rhythm; Diffuse ST depression with ST elevation in aVF, consistent with severe global ischemia; Premature ventricular complexes now present; Short PR interval now present; Prolonged QT interval now present.

Clinical Imaging Reports

(a) CT without Contrast

Severe diffuse pancolonic diverticulosis without evidence of diverticulitis.

(b) CT with Contrast

Active GI bleeding most likely diverticular from the proximal portion of the right hepatic flexure.

(c) Nuclear Medicine Technetium-99 Scan

Focus of tracer accumulation is in the region of the distal right colon and hepatic flexure, consistent with the site of active GI bleeding. Correlation with the CT, this is likely a diverticular bleed.

(d) Angiogram Embolization

Successful prophylactic embolization of the distal right colic artery in the region of the distal ascending colon near the area of arterial extravasation seen on recent CTA. If the GI bleed does not successfully stop, consider further intervention with colonoscopy versus partial colectomy.

Figure 3: Impressions from the imaging done with this patient: CT without contrast (a), CT with contrast (b), NM Technetium-99 scan (c), and angiogram with embolization (d). None of the images listed above were able to locate the bleed from the Meckel's diverticulum.

Pathology Report

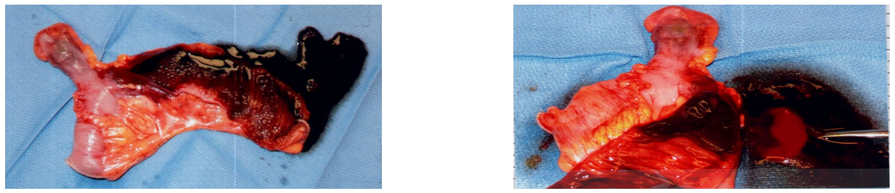

Figure 4: Gross specimen consisting of the infarcted Meckel's diverticulum and portions of ileum. Mild acute inflammation is present within the mucosa. The Meckel's diverticulum, located adjacent to the purple dusky area, measures 4.5 cm in length and 1.5-2.3 cm in width. The ileum measures 17.0 cm in length, with a circumference ranging from 4.0 to 5.0 cm.

Laboratory Tests

Table 1: Initial Emergency Room Laboratory Values

CBC	Patient Value	Reference Range
WBC	16.3	4.8-10.8 K/cumm
Hemoglobin	6.7	13.9-16.3 g/dL
Hematocrit	21.4	39.0-55.0 %
RBC	2.3	4.30-5.90 M/uL
Platelets	214	130-375 K/uL
Additional labs	**Patient Value**	**Reference Range**
Lactic acid (v)	3.8	0.4-2.0 mmol/L
Troponin	0.36	< 0.04 ng/mL
FOBT	Positive	-

Table 2: Pre-exploratory laparotomy Laboratory Values

CBC	Patient Value	Reference Range
WBC	11.9	4.8-10.8 K/cumm
Hemoglobin	8.5	13.9-16.3 g/dL
Hematocrit	25.7	39.0-55.0 %
RBC	2.91	4.30-5.90 M/uL
Platelets	84	130-375 K/uL
Additional labs	**Patient Value**	**Reference Range**
Lactic acid (v)	0.9	0.4-2.0 mmol/L
Troponin	4.05	< 0.04 ng/mL
FOBT	-	-

Discussion

- **What caused this presentation?**
  - The Meckel's diverticulum twisted around bowel causing ischemia and necrosis of the diverticulum and surrounding small bowel.
  - The GI bleed caused by the infarcted bowel likely induced a demand myocardial ischemia, leading to cardiac symptoms and EKG changes.
- **What was our clinical rationale?**
  - Concerns of myocardial ischemia prompted treatment with nitroglycerin.
  - Patient's symptoms and laboratory values showing anemia led to several blood transfusions.
  - Initial imaging studies did not demonstrate evidence of a GI bleed. Therefore, no immediate action was taken.
  - Patient's recurring falls in hemoglobin levels, along with failed attempts at embolizing the bleed via interventional radiology, prompted additional investigation via exploratory laparotomy.
- **What did we learn?**
  - Earlier detection of Meckel's diverticulum can decrease risk of mortality and severe complication.
  - Do not completely rule out a bleeding Meckel's diverticulum if it does not show up on imaging; The only way to be certain is to examine surgically.
  - This presentation could have been managed more efficiently by pursuing an exploratory laparotomy earlier after a lower number of blood transfusions.
  - GI bleeds can put stress on other organs of the body, such as the heart, leading to cardiac pathology.

Conclusion

- Congenital anomalies, such as a Meckel's diverticulum, do not always present in childhood.
- Generate a wide differential and consider atypical presentations when evaluating a GI bleed.
- GI bleeds can place a stress on the heart, particularly in patients with cardiac compromise.
- Staying up to date on current literature promotes positive patient outcomes.